

See discussions, stats, and author profiles for this publication at: <https://www.researchgate.net/publication/330077807>

Texture Analysis on Thyroid Ultrasound Images for the Classification of Hashimoto Thyroiditis

Chapter · January 2019

DOI: 10.1007/978-3-030-04061-1_28

CITATION

1

READS

317

2 authors:



[Kohila S.](#)

VV Vanniaperumal College for Women

12 PUBLICATIONS 64 CITATIONS

[SEE PROFILE](#)



[Dr Sankara Malliga G](#)

Anand Institute of Higher Technology

13 PUBLICATIONS 28 CITATIONS

[SEE PROFILE](#)

Texture Analysis on Thyroid Ultrasound Images for the Classification of Hashimoto Thyroiditis



S. Kohila and G. Sankara Malliga

Abstract The biopsy using Fine Needle Aspiration (FNA) is a major procedure/testing method which has been regularly recommended, at a time, exactly when a thyroid nodule is suspected or else identified. The FNA will usually reveal if a nodule is benign or malignant. Histopathology is also sometimes recommended. Another regular test is the ultrasound. Yet, the ultrasound cannot recognize or distinguish the thyroid disorders. Hashimoto thyroiditis is the most widely recognized kind of inflammation of the thyroid gland. The motto of this work is to identify the Hashimoto's thyroiditis disorder using only ultrasonogram images without going for any painful examination. In this paper, features are studied using the Neighborhood Gray Tone Difference Matrix (NGTDM), Statistical Feature Matrix (SFM), and Laws' texture energy measures methods. The salient features from the above procedures are helpful to identify and in separating the two types of ultrasonic thyroid images as normal and Hashimoto's thyroiditis. The student two-tailed unpaired T-test method is employed to classify the two groups. A major difference between the two groups ($p < 0.001$) was observed. The results are correlated with the histopathology results. The results prove that the Hashimoto thyroiditis can be identified using the ultrasound images.

Keywords Texture analysis · T-test · Hashimoto thyroiditis · NGTDM · SFM
Laws' texture energy measures · Thyroiditis

S. Kohila (✉)
Department of Electronics and Communication Engineering,
Sri Sairam Engineering College, Chennai, India
e-mail: kohila.ece@sairam.edu.in

S. Kohila
VELS University, Chennai, India

G. Sankara Malliga
Department of Electronics and Communication Engineering,
Anand Institute of Higher Technology, Chennai, India
e-mail: sankaramalliga@gmail.com

1 Introduction

The thyroid gland is a kind of endocrine gland which is bigger like many types. It will be found in neck region, underneath the thyroid cartilage. Common thyroid disorders are hyperthyroidism, hypothyroidism, thyroiditis, and thyroid nodules. In this study, an application of a technique is suggested which is used for the automatic findings of Hashimoto's thyroiditis using only the ultrasonogram images [1].

Thyroiditis is an inflammation of the thyroid organ or gland that can emerge due to a variety of reasons. There are two sorts of thyroiditis where at first hyperthyroidism presents that is trailed before the occurring time matched to hypothyroidism. There exist postpartum thyroiditis and Hashimoto's thyroiditis.

Generally, thyroid issues can be analyzed from clinical examinations utilizing immunological, metabolic, and also hormonal investigations of examining blood as well as cytological testing utilizing the FNA biopsy. Nevertheless, the commonly utilized demonstrative and observing tool for the thyroid issues happens to be the ultrasonogram imaging.

Nowadays, through clinical methods like histopathology examination and via FNA cytology, the swelling in thyroid nodule has been determined. Despite the fact that the consequences of FNA cytology and histopathological tests are exact, they have disadvantages as arrangements to provide anesthesia, hospital admission, and needle inclusion. But the ultrasonography is a noninvasive technique. It also has the uniqueness like real-time imaging, low cost, ableness to analyze different dimensions and the effect of volume, mobile nature, and the quality of not having side impact. Thus, the ultrasonogram imaging has become the widely utilized strategy in imaging for examining and executing follow up actions for thyroid-related disorders.

Just a couple of studies have concentrated on creating computational ways to deal with thyroid features analysis by ultrasound image examination. Image intensity details are utilized with a view to have the recognizable proof of the disorder of thyroid Hashimoto's [2], with a view to mark the identification of lesions in nodular thyroid [3], and also with a view related to tumor characterization [4]. The textural information extracted from the image using the co-occurrence matrix characteristics [5] are used to mark recognizable proof for identifying the chronic inflammations of thyroid gland [6] as well as for segregation process among the very usual and pathologic tissues [7]. Texture features using GLCM and GRLM for the ultrasonogram images of Hashimoto thyroiditis are discussed [8].

The evaluation of sonographic identification of deeply chronic inflamed thyroid tissue is much related to examiner's understanding and experience. This paper shows that correct assessment is possible that inflamed and healthy tissues can be distinguished by the methods explained. This work is an initial step to quantitative investigation of the chosen area of vital importance. A smaller number of texture features computed from the ultrasonogram images proved that it is possible to achieve high classification rate to discriminate the Hashimoto's thyroiditis and healthy tissue.

In this paper, the attributes to classify the Hashimoto's thyroiditis and normal images of ultrasound images are focused. They are currently observed using either

FNAC or histological methods. The different features from the ultrasound images are extracted using the methods NGTDM, Laws' texture energy measures, and statistical feature matrix texture analysis. The student two-tailed unpaired T-Test is used for the analysis of the extracted features. Significant differences are observed between the two groups normal and Hashimoto's thyroiditis.

This presentation is structured like below. The materials and methods have been discussed in Sect. 2. Texture analysis using NGTDM and the statistical feature matrix is presented in Sects. 3 and 4, respectively. Section 5 deals Laws' texture energy measures. Results are discussed in penultimate Sect. 6, and the last Sect. 7 has the summation with conclusions.

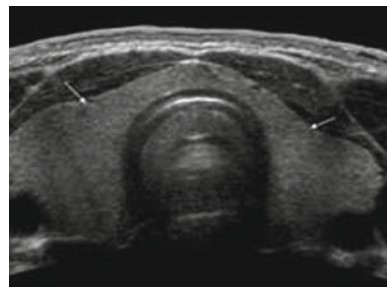
2 Materials and Methods

2.1 Data Acquisition

To begin with, the ultrasound images of 14 patients affected by Hashimoto's thyroiditis and simultaneously 25 people with non-complaints related to thyroid were accumulated from Bharat Scan Centre, Royapettah, Tamil Nadu. These images were analyzed and the findings of Hashimoto's thyroiditis had been confirmed by means of the reports of histopathology.

An ultrasound image of a normal thyroid gland (without nodules) is exhibited in Fig. 1. The automatic detection and segmentation of thyroid images with and without nodule have been complex and the segmentation processing has not been in the observation of this paper. A tool which is interacting is utilized. The boundaries of nodules are generally marked by the physician as illustrated by the outline in Fig. 2. Number of $M \times M$ non-overlapping images are manually cropped and selected as samples. The features have been extracted from the accumulated images using the aforementioned methods like, Neighborhood Gray Tone Difference Matrix (NGTDM), texture analysis using statistical feature matrix, and Laws' texture energy measures techniques. Significant features were selected using student T-test.

Fig. 1 Ultrasound image of thyroid gland (without nodules)



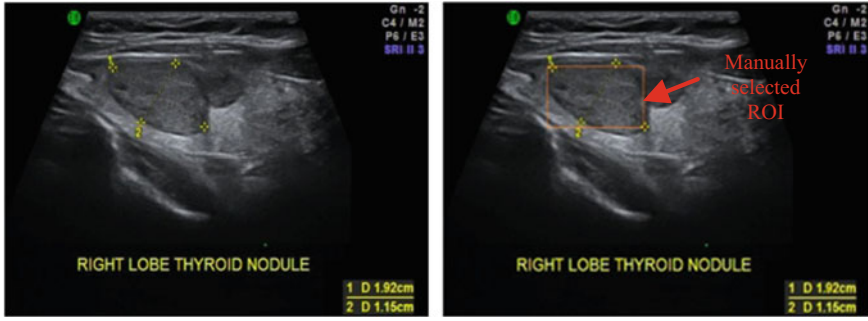


Fig. 2 Ultrasound image of thyroid gland (with nodules)

3 Neighborhood Gray Tone Difference Matrix (NGTDM)

The properties that are used to separate between different textures include complexity, coarseness, contrast, busyness (finess), directionality, shape, and texture strength. Therefore, for the general texture measures and performance analysis in automatic texture classification, the aforementioned textural properties are included.

The visual properties which are characterized using coarseness, busyness, complexity, contrast, and texture strength are considered as very vital texture descriptions in view of concepts by people in a broader way [9]. These properties were expressed by equations using the neighborhood gray tone difference matrix technique.

Coarseness refers to the roughness of the image and related to the small number of large primitives. The computational measure for coarseness property is given in Eq. 1

$$f_{\text{coar}} = \left[\epsilon' + \sum_i^{G_m} p_i + C(i) \right]^{-1} \tag{1}$$

where G_m is the maximum gray level present in the image and ϵ' is a constant that prevents f_{coar} attaining infinite. For an $M \times N$ image, P_i is the probability of occurrence of intensity value i , and is given by Eq. 2

$$P_i = N_i / \text{Total number of pixels} \tag{2}$$

The f_{coar} is the coarseness.

Contrast means the distinction of the things which are brought for comparison. The computational form for this property is given in Eq. 3

$$f_{\text{con}} = \left[\frac{1}{N_g(N_g - 1) \sum_{i=0}^{G_n} \sum_{j=0}^{G_n} P_i P_j (i - j)^2} \right] \left[\frac{1}{n^2 \sum_i^{G_n} S(i)} \right] \tag{3}$$

where N_g is the number of different intensity levels present in the image and can be expressed as in Eq. (4)

$$N_g = \sum_i^{G_k} Q_i \quad (4)$$

where

$$Q_i = \begin{cases} 1, & \text{if } P_i \neq 0 \\ 0, & \text{otherwise} \end{cases}$$

Busyness is appearing to be actively engaged in an activity. The computational measure is given in Eq. 5

$$f_{\text{bus}} = \sum_i^{G_n} P_i S(i) / \sum_i^{G_n} \sum_i^{G_n} i P_i - j P_j \quad (5)$$

where $P_i \neq 0, P_j \neq 0$

Complexity refers to the quality of the image and useful in determining the compression techniques. The computational measure is given in Eq. 6

$$f_{\text{comp}} \sum_i^{G_n} \sum_j^{G_n} \{(|i - j|) / (n^2 (P_i + P_j))\} \{P_i S(i) + P_j S(j)\} \quad (6)$$

where $P_i \neq 0, P_j \neq 0$

The feature strength is expressed in Eq. 7

$$f_{\text{str}} = \left[\sum_i^{G_n} \sum_j^{G_n} (P_i + P_j)(i - j)^2 \right] / \left[+ \sum_i^{G_n} S(i) \right] \quad (7)$$

where $P_i \neq 0, P_j \neq 0$.

Among these five NGTDM features, the four features coarseness, complexity, contrast, and strength are employed in the work to point out various features from thyroid ultrasound images of Hashimoto's thyroiditis.

4 Statistical Feature Matrix (SFM)

The visual textures suggested by the author [10, 11] are extracted and analyzed. SFM measures the statistical properties of two pixels within an image at various distances. It depends on the size of the matrix rather than the gray value. The following features are extracted using SFM:

- Coarseness When there is a difference, only in scale between the two patterns, the magnified one is coarser.
- Contrast Image contrast is either shrinking or stretching the intensity scale.
- Periodicity It is due to the regularity of repetitive patterns.
- Roughness It occurs because of mock energy changes in gray levels.

The above features are extracted and analyzed.

5 Laws' Texture Energy Measures

To measure the amount of variation in the image a texture energy approach was developed by Laws [12, 13]. The energy depends on fixed size window. To extract energy from the normal and abnormal images, local averaging, edge and spot mask of size 1×3 are used. A center weighted local averaging mask, $L = (1, 2, 1)$, an edge mask $E = (-1, 0, 1)$, and spot detection mask $S = (-1, 2, -1)$ are applied to obtain texture energy from the images. By convolving L , E , and S masks with each other the 3×3 mask kernel of LL , EE , SS , LS , LE , and ES are obtained. Further, 3×3 mask, LL , EE , SS , LE , SE , and LS are convolved with images and texture energy is extracted. The extracted texture feature is analyzed to differentiate the normal and Hashimoto thyroiditis tissues.

6 Results

A sum of 585 salient feature values is extracted using MATLAB coding. 15 features for each of 39 samples had been computed, extracted, and the above features are utilized for the purpose of analysis. Student T-test was conducted between the ultrasound images of Hashimoto's thyroiditis and normal thyroid ultrasound images and is presented in Table 1. The features that express significant differences between two groups are explicitly shown in Table 2. The significant features that distinguish the two groups are selected based on the T-test results. They are selected with a greater significance of $p < 0.005$. Depending on the T-test analysis, the features coarseness, contrast, complexity, strength, periodicity, roughness and the Laws' TEM features can be utilized to distinguish the normal and Hashimoto's thyroiditis using ultrasonogram images. The varied observations between the two groups for different p -values ($p < 0.05$, $p < 0.005$, and $p < 0.0005$) were presented in Table 2.

The evaluation of inflamed chronic thyroid using ultrasound images in medical practice is based on experience of the examiner or medical practitioner. But, the literature studies show that the correct assessment is possible, and the normal and inflamed thyroid tissues can be differentiated by texture analysis [1–8]. Similarly, the proposed texture features extracted from ultrasonogram images were also shown higher significance toward classification abnormality in the thyroid glands. Acharya

Table 1 T-test analyses on the features extracted

Texture features	T-test	<i>p</i> -value B/N normal and Hasi
NGTDM	Coarseness	0.00170
	Contrast	0.00164
	Busyness	0.02860
	Complexity	0.00000
	Strength	0.00000
SFM	Coarseness	0.00042
	Contrast	0.00000
	Periodicity	0.00000
	Roughness	0.00000
Laws' TEM	LL	0.00000
	EE	0.00000
	SS	0.00000
	LE	0.00002
	ES	0.00000
	LS	0.00001

Table 2 Variation between the groups for different *p*-values ($p < 0.05$, $p < 0.005$, and $p < 0.0005$)

Variables/Groups	Normal (n = 25)	Hasi (n = 14)	<i>p</i> -value (a)
Age	44.72 ± 13.24	35.57 ± 12.14	0.069
Coarseness	59.11 ± 16.92	42.86 ± 7.77	0.00170
Contrast	0.04 ± 0.02	0.09 ± 0.08	0.00164
Busyness	0.02 ± 0.04	0.07 ± 0.02	0.02860
Complexity	11836.66 ± 18745.56	63402.29 ± 30811.92	0.00000
Strength	495803.11 ± 298823.43	1409014.74 ± 558705.02	0.00000
Coarseness	14.51 ± 4.05	9.96 ± 2.23	0.00042
Contrast	6.16 ± 2.97	12.44 ± 3.32	0.00000
Periodicity	0.76 ± 0.08	0.64 ± 0.03	0.00000
Roughness	2.14 ± 0.05	2.29 ± 0.08	0.00000
LL	64886.34 ± 8808.52	108732.25 ± 27489.09	0.00000
EE	580.48 ± 344.46	1232.45 ± 314.67	0.00000
SS	54.04 ± 49.34	187.25 ± 66.57	0.00000
LE	5025.06 ± 1652.83	7764.23 ± 1741.15	0.00002
ES	166.51 ± 134.93	463.87 ± 134.8	0.00000
LS	1288.11 ± 691.91	2482.28 ± 635.23	0.00001

et al. [1] extracted similar kind of features from ultrasonogram images for classification of Hashimoto's thyroiditis. The vital texture features such as roughness, strength, and morphology were already used in other clinical image analysis application such as classifying osteoporosis from images of X-ray as well as the Computed Tomography (CT) images [14].

7 Conclusion

This paper shows that Hashimoto's thyroiditis can be a different kind from a normal or very usual kind of thyroid gland using the findings through the texture analysis process of ultrasound images. Since this can be evaluated with a number of features (nine), the result confirms that the feature characteristics which are extracted from the ultrasound images of thyroid can be used to characterize the image. Best classification results can be obtained by applying the extracted features as input for a classifier.

References

1. Acharya UR, Vinitha Sree S, Mookiah MRK, Yantri R, Molinari F, Zieleźnik W, Małyszczek-Tumidajewicz J, Stępień B, Bardales RH, Witkowska A, Suri JS (2013) Diagnosis of Hashimoto's thyroiditis in ultrasound using tissue characterization and pixel classification. *Proc Inst Mech Eng [H]* 227(7):788–798
2. Chang CY, Chen SJ, Tsai MF (2010) Application of support-vector-machine-based method for feature selection and classification of thyroid nodules in ultra sound images. *Pattern Recogn* 43(10):3494–3506
3. Haralick RM, Shanmugam K (1973) Textural features for image classification. *IEEE Trans Syst Man Cybern* 6:610–621
4. Tomimori EK, Camargo RY, Bisi H, Medeiros-Neto G (1999) Combined ultrasonographic and cytological studies in the diagnosis of thyroid nodules. *Biochimie* 81(5):447–452
5. Maroulis DE, Savelonas MA, Iakovidis DK, Karkanis SA, Dimitropoulos N (2007) Variable background active contour model for computer-aided delineation of nodules in thyroid ultrasound images. *IEEE Trans Inf Technol Biomed* 11(5):537–543
6. Kousarrizi MN, Seiti F, Teshnehlab M (2012) An experimental comparative study on thyroid disease diagnosis based on feature subset selection and classification. *Int J Electr Comput Sci IJECS-IJENS* 12(01):13–20
7. Tsantis S, Dimitropoulos N, Cavouras D, Nikiforidis G (2009) Morphological and wavelet features towards sonographic thyroid nodules evaluation. *Comput Med Imag Graph* 33(2):91–99
8. Kohila S, Malliga GS (2016) Classification of the thyroiditis based on characteristic sonographic textural features and correlated histopathology results. In: *IEEE international conference on signal and image processing (ICSIP)*. IEEE, pp 305–309
9. Amadasun M, King R (1989) Textural features corresponding to textural properties. *IEEE Trans Syst Man Cybern* 19(5):1264–1274
10. Wu CM, Chen YC (1992) Statistical feature matrix for texture analysis. *CVGIP: Graph Models Image Process* 54(5):407–419
11. Chang CY, Tsai MF, Chen SJ (2008) Classification of the thyroid nodules using support vector machines. In: *2008 IEEE international joint conference on neural networks, IJCNN 2008. (IEEE world congress on computational intelligence)*. IEEE, pp 3093–3098

12. Laws KI (1979) Texture energy measures. In: Proceedings of a workshop on Image understanding workshop, pp 47–51
13. Wu CM, Chen YC, Hsieh KS (1992) Texture features for classification of ultrasonic liver images. *IEEE Trans Med Imaging* 11(2):141–152
14. Sathagirivasan V, Anburajan M (2013) Diagnosis of osteoporosis by extraction of trabecular features from hip radiographs using support vector machine: an investigation panorama with DXA. *Comput Biol Med* 43(11):1910–1919